

Available online at www.sciencedirect.com

SciVerse ScienceDirect

journal homepage: <http://www.elsevier.com/locate/aob>

Alveolar bone loss associated to periodontal disease in lead intoxicated rats under environmental hypoxia

Antonela R. Terrizzi^a, Javier Fernandez-Solari^{a,c}, Ching M. Lee^a,
Clarisa Bozzini^a, Patricia M. Mandalunis^b, Juan C. Elverdin^a,
María Ines Conti^a, María Pilar Martínez^{a,*}

^aDepartment of Physiology, Faculty of Dentistry, University of Buenos Aires, Argentina

^bDepartment of Histology, Faculty of Dentistry, University of Buenos Aires, Argentina

^cNational Council for Scientific and Technical Research (CONICET), Argentina

ARTICLE INFO

Article history:

Accepted 12 June 2013

Keywords:

Lead poisoning
Environmental hypoxia
Bone loss
Periodontitis

ABSTRACT

Previously reported studies from this laboratory revealed that rats chronically intoxicated with lead (Pb) under hypoxic conditions (HX) impaired growth parameters and induced damages on femoral and mandibular bones predisposing to fractures. We also described periodontal inflammatory processes under such experimental conditions. Periodontitis is characterised by inflammation of supporting tissues of the teeth that result in alveolar bone loss. The existence of populations living at high altitudes and exposed to lead contamination aimed us to establish the macroscopic, biochemical and histological parameters consistent with a periodontal disease in the same rat model with or without experimental periodontitis (EP). Sixty female rats were divided into: Control; Pb (1000 ppm of lead acetate in drinking water); HX (506 mbar) and PbHX (both treatments simultaneously). EP was induced by placing ligatures around the molars of half of the rats during the 14 days previous to the autopsy. Hemi-mandibles were extracted to evaluate bone loss by histomorphometrical techniques. TNF α plasmatic concentration was greater ($p < 0.01$) in Pb and HX animals. TBA-RS content was significantly higher in gums of rats with or without EP only by means of Pb. The SMG PGE₂ content increased by Pb or HX was higher in PbHX rats ($p < 0.01$). Pb and HX increased EP induced alveolar bone loss, while Pb showed spontaneous bone loss also. In conclusion, these results show that lead intoxication under hypoxic environment enhanced not only alveolar bone loss but also systemic and oral tissues inflammatory parameters, which could aggravate the physiopathological alterations produced by periodontal disease.

© 2013 Elsevier Ltd. All rights reserved.

1. Introduction

More than 200 million people live at altitudes above 2500 m around the world frequently exposed to environmental pollutants. Among these, lead (Pb) is of particular interest

because of its wide distribution in the environment. Previously reported studies from this laboratory suggested that chronic intoxication with Pb in immature rats under hypoxic conditions impaired growth parameters and induced negative effects on femoral and mandibular structural properties decreasing their maximal load supported at fracture and their

* Corresponding author at: Marcelo T. de Alvear 2142 3A, 1122 Buenos Aires, Argentina. Tel.: +54 11 4964 1275; fax: +54 11 4508 3958.

E-mail addresses: pilarmartinez@fsio.odon.uba.ar, pilarmartinez@fibertel.com.ar (M.P. Martínez).

0003-9969/\$ – see front matter © 2013 Elsevier Ltd. All rights reserved.

<http://dx.doi.org/10.1016/j.archoralbio.2013.06.010>

energy absorption capacity so that plastic deformation and failure in bone tissue structure occurred under lower loads.¹ Chronic exposure to lead (Pb) significantly affects oral health condition among exposed workers increasing the prevalence of periodontal diseases (gingivitis and periodontitis) and in the prevalence of decay (caries), missed and filled teeth and dental abrasions.^{2,3} Epidemiologic investigations in high altitude territory showed that the hypoxia environment plays an important role in the pathogenesis of periodontitis and it was demonstrated in rats that the course of periodontitis in altitude hypoxia environment is later than normal, but the degree of periodontal lesion was more severe.⁴ Periodontitis is characterised by inflammation of the supporting tissues of the teeth and periodontal pocket formation that result in alveolar bone resorption and soft tissue attachment loss. It has been suggested that the submandibular gland is a key regulatory organ in the oral neuroimmunoregulatory network.⁵ We recently reported in growing rats chronically intoxicated with lead (Pb) and exposed to the stress of intermittent hypobaric hypoxia (HX) deleterious effects on periodontal and dental tissues that could be due to a greater vulnerability of them to inflammatory processes.¹ Furthermore, it was demonstrated that animals co-exposed to lead and fluoride show more severe damage than lead alone,⁶ which suggests the complex interaction between lead and other environmental factors and the importance of studying them together. These findings and the existence of populations living at high altitudes and exposed to lead contamination aimed us to establish in the same rat model, the macroscopic, biochemical and histological parameters consistent with a periodontal disease and whether they are or not enhanced in rats submitted to experimental periodontitis (EP). The results will try to cover the lack of information regarding the oral health in individuals living in lead contaminated high altitude areas.

2. Materials and methods

2.1. Animals, treatments and induction of periodontal disease

Sixty Wistar rats were randomly divided into 4 groups: C (control); Pb (intoxicated with 1000 ppm of lead acetate in drinking water for 3 months)⁷; HX (exposed to 18 h/d by placing the animals into a chamber at 506 mbar for 3 months)⁸ and PbHX (both treatments simultaneously). EP was induced in half of the animals of each group under general anaesthesia with a mixture of 2% xylazine hydrochloride (5 mg/kg; i.p. König Laboratories) and 5% ketamine hydrochloride (50 mg/kg; i.p. Holliday-Scott SA) by placing a cotton thread ligature around the neck of the first lower molars (FLM) during the 14 days previous to the autopsy.⁹ At the end of the experimental period, blood samples were obtained by cardiac puncture to assess hematocrit by micromethod. Pb content in bone ashes was determined using an atomic absorption spectrophotometer Varian AA 475.

All animals were treated in accordance with the guidelines and regulations for the use and care of animals of the University of Buenos Aires Ethic Committee and were carried out in accordance with the guidelines of the National Institute

of Health (NIH). The use of animal tissues followed an approved animal use protocol.

2.2. Measurement of proinflammatory and oxidative stress markers

At the end of the experimental period blood samples were collected to assess hematocrit by micromethod and lead content using an atomic absorption spectrophotometer Varian AA 475. TNF α concentration was determined using a sandwich ELISA according to the manufacturer's instructions (BD Pharmingen, USA).¹⁰

Thiobarbituric acid reactive substances (TBA-RS) were evaluated in gingival tissues and SMG quantifying malondialdehyde (MDA) as the product of lipid peroxidation that reacts with trichloroacetic acid-HCl, yielding a pink-stained TBA-RS determined in a spectrophotometer (Hitachi U-2001) at 540 nm. TBA-RS were calculated as nanomoles per milligramme of tissue.¹¹

2.3. Radioimmunoassay of PGE2

To evaluate PGE content, submandibular glands were homogenised in 1.5 ml ice cold ethanol (100%), centrifuged at 10,000 $\times g$ for 15 min at 4 °C, and the supernatant were collected and evaporated in a Speed-Vac. The residues were re-suspended with radioimmunoassay buffer and the Sigma antiserum was used. The PGE content was expressed as pg/mg of weight tissue.¹²

2.4. Microscopic examination of periodontal bone loss: distance method

After autopsy, the hemi-mandibles were resected, defleshed and stained with 1% aqueous methylene blue to delineate the cemento-enamel junction (CEJ) and the alveolar crest (AC).

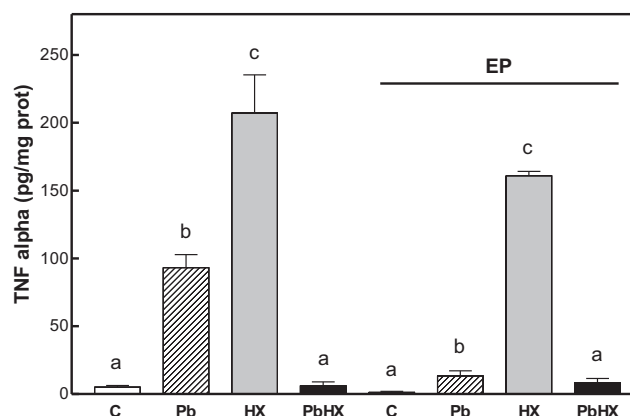


Fig. 1 – Effect of Pb (1000 ppm of lead acetate in drinking water for 3 months); HX (18 h/d at 506 mbar for 3 months) and PbHX (both treatments simultaneously) on TNF α release, in rats with and without EP. Line in graph show animals submitted to EP. Mean \pm SD of 15 rats. Equal letters indicate no significant differences. A significant difference between groups was chosen as $p < 0.01$ determined by two-way ANOVA followed by Student–Newman–Keuls Multiple Comparison Test.

A stereomicroscope (Stemi DV4 Stereomicroscope, Carl Zeiss MicroImaging, Göttingen, Germany) and a digital calliper (Digimess, Geneva, Switzerland) were used to measure three lingual/palatal and three buccal distances (mesial, central and distal) from the CEJ to the most apical area of the AC. The sum of the three distances on each side of each molar was used as a measure of the alveolar bone loss in millimeters¹⁰ (Fig. 3, Upper).

2.5. Statistic

Statistical analyses were performed by two-way ANOVA followed by multiple comparison Student–Newman–Keuls tests (GraphPad Software Inc., San Diego, USA).

3. Results

3.1. Hematocrit % and lead content

Significantly high-level lead accumulation was observed in ashes from bones in Pb (640.53 ± 86.32 mg/g) and PbHX (695 ± 63.23 mg/g) groups against control animals (0.98 ± 0.35 mg/g) indicating that the administered Pb was deposited in the skeleton in significant amounts. Exposure of rats to hypobaric hypoxia produced an expected significant increase in hematocrit values (C: 43.51 ± 3.07%; Pb: 35.08 ± 4.11%; HX: 74.05 ± 7.04% and PbHX: 61.37 ± 5.91%).

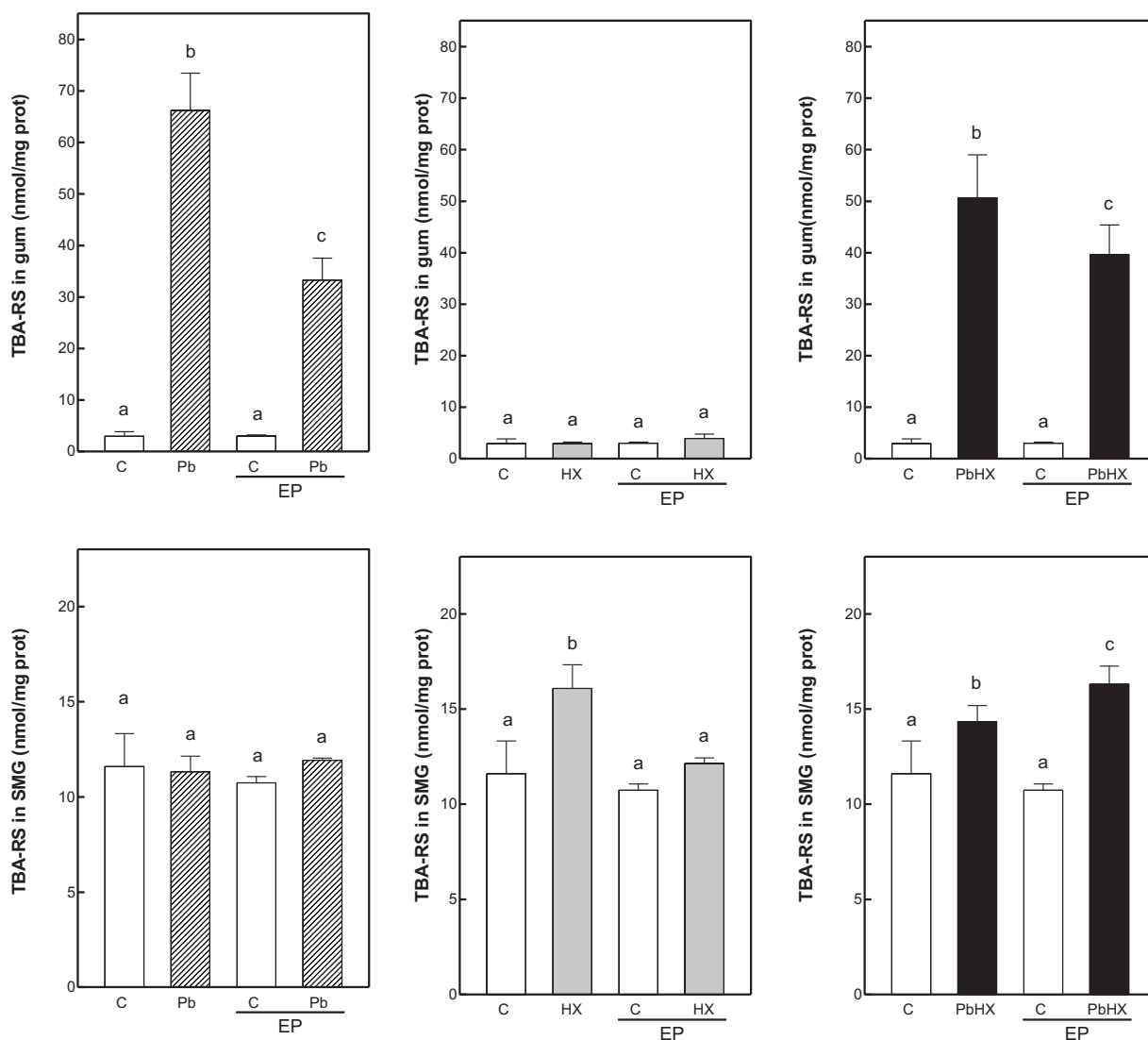


Fig. 2 – Effect of Pb (left), HX (middle) and the combination of both treatments (right) on TBA-RS content in gum (UPPER) and SMG (DOWN) from rats with or without bilateral EP. Data are reported as means ± SD (15 rats per group. EP was induced in half of the animals of each group). Equal letters indicate no significant differences. A significant difference between groups was chosen as $p < 0.01$ determined by two-way ANOVA followed by Student–Newman–Keuls Multiple Comparison Test.

3.2. Plasmatic TNF alpha content

We observed a significant increased concentration of TNF α in the group intoxicated with lead ($p < 0.01$) against the control group being the enhancement even greater in the group exposed to HX. When both treatments were applied simultaneously, no significant difference against the control group was observed. The same response pattern was observed in the EP groups (Fig. 1).

3.3. TBA-RS content in gingival tissue (gums) and SMG

In order to explore the effect of treatments on some oral target tissues before or after periodontitis induction, we first evaluated an oxidative stress marker that might be modified in inflammatory processes such as TBA-RS in gingival tissue and salivary glands. Rats chronically intoxicated with lead showed significant higher values of TBA-RS content in gums, but not in SMG. On the contrary, hypoxia significantly enhanced TBA-RS content in SMG, but not in gums. These results were independent of the existence or not of EP (Fig. 2).

3.4. PGE₂ content in SMG

PGE₂ content, measured by RIA, was increased in every experimental group against its control in rats with and without EP. The group with lead intoxication under hypoxia environment showed even higher values (Fig. 3).

3.5. Microscopic examination of periodontal bone loss: distance method

Regarding alveolar bone loss, we measured the distance in mm between the enamel-cement junction and the alveolar crest, in lingual and buccal side of the mandible. In every experimental group, no significant difference against the control group was observed in the animals without EP (with

the exception of HX animals in the buccal side). We observed bone loss in the control group with EP, which was increased not only by lead intoxication (Fig. 4A) but also by exposition to HX (Fig. 4B) or by means of both treatments applied simultaneously (Fig. 4C).

3.6. Interradicular bone volume

Interradicular bone volume was measured using Image Pro Plus software, expressed as % of total bone volume. Significant bone loss was observed in the control group with EP, being even higher in those rats with EP exposed to HX and with both treatments simultaneously. Furthermore, the PbHX rat was the only group that showed interradicular bone loss when the experimental periodontitis was not applied (Fig. 5).

4. Discussion

In this paper, we demonstrated that chronic lead intoxication under normoxic and hypoxic environment modify some systemic and oral tissues inflammatory parameters, which could lead to a periodontal disease in individuals living in lead contaminated high altitude areas. Periodontitis is an infectious disease characterised by inflammation of tooth-supporting tissues and by periodontal pocket formation, which results in alveolar bone resorption and loss of periodontal attachment tissue with evidence indicating the role of submandibular glands in the regulation of immune/inflammatory reactions.⁹ It may be influenced by several environmental factors. Among these, the effects of Pb or hypobaric hypoxia on oral health are of particular relevance to understanding the pathogenesis of periodontitis in populations living and working in areas lead contaminated at high altitude. It was demonstrated, in a rat model under hypoxic conditions, that the degree of periodontal lesions and the microbial community in gingival crevicular fluid were affected by the altitude hypoxia environment.⁴ Oral

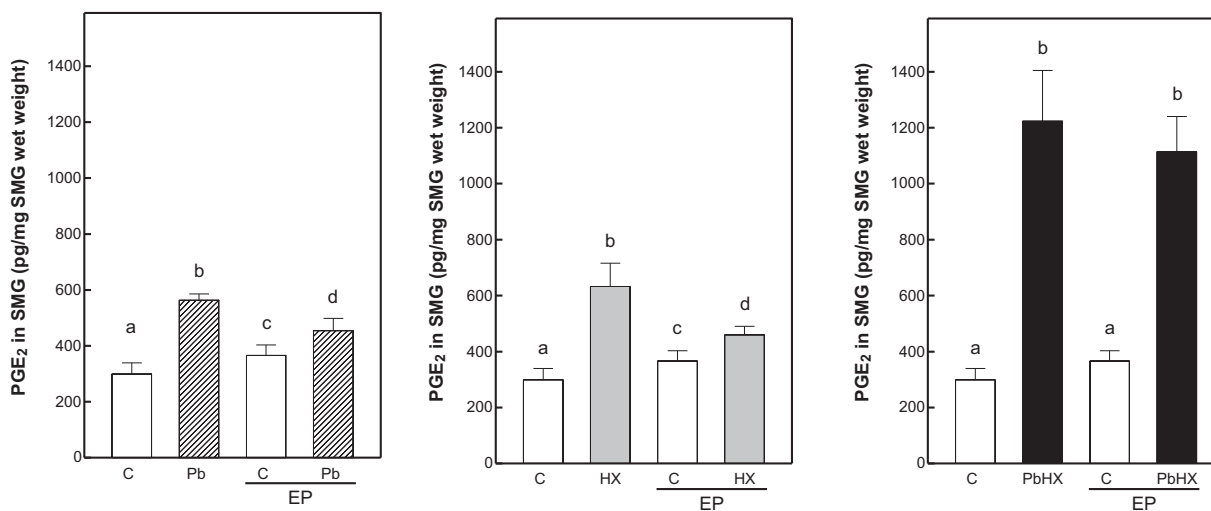


Fig. 3 – Effect of Pb (left), HX (middle) and the combination of both treatments (right) on PGE₂ content in SMG from rats with or without bilateral EP. Data are reported as means \pm SD (15 rats per group. EP was induced in half of the animals of each group). Equal letters indicate no significant differences. A significant difference between groups was chosen as $p < 0.01$ determined by two-way ANOVA followed by Student–Newman–Keuls Multiple Comparison Test.

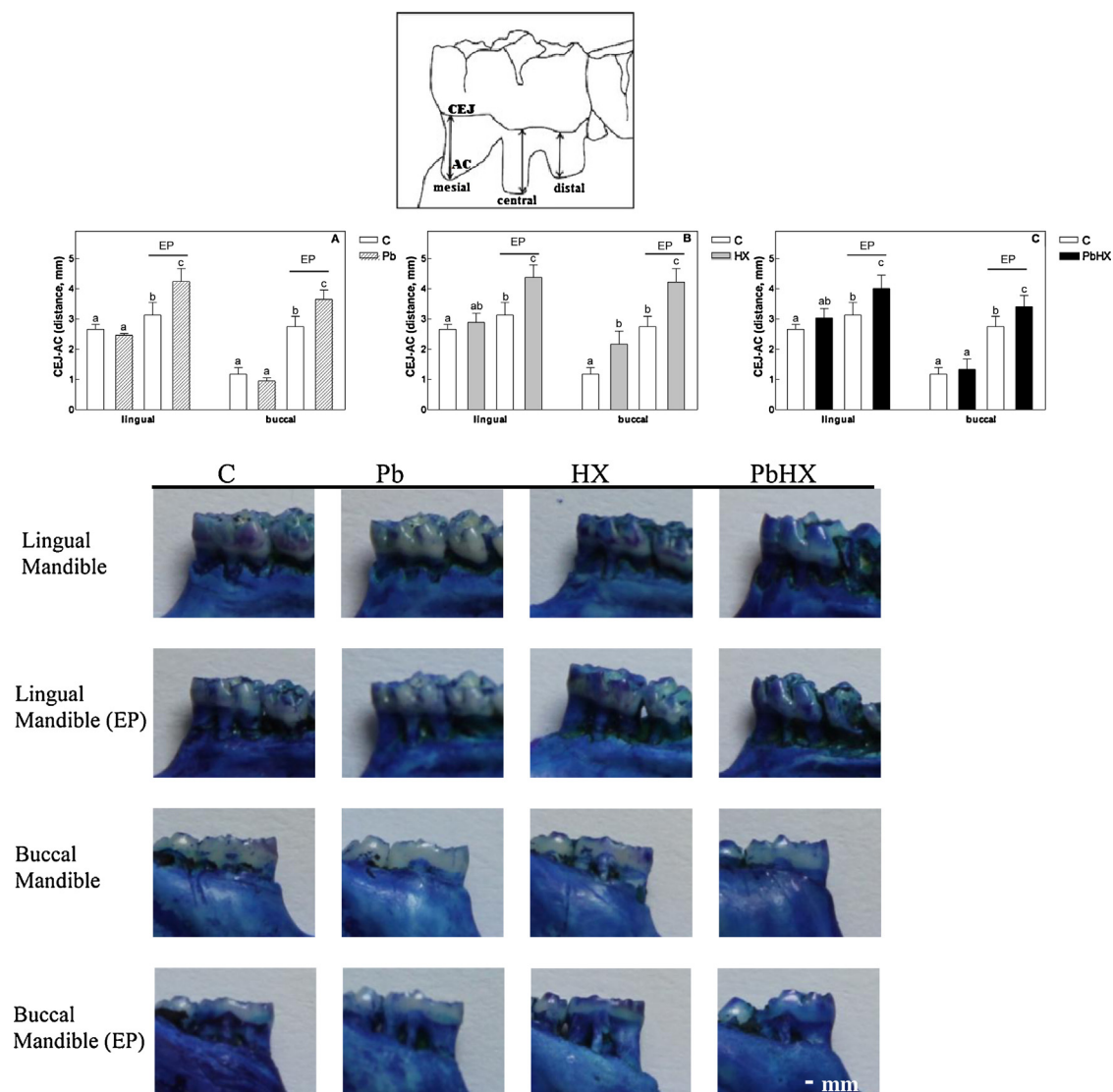


Fig. 4 – Effect of alveolar bone loss after Pb and HX treatments in rats with 14-days experimental periodontitis (EP). Upper: Distance method: diagram of a section of the lower first molar. Three distances (arrows) were measured from the cement-enamel-junction (CEJ) to the most apical area of the alveolar crest (AC). Middle: Measurements by distance method showing lingual and buccal sections of mandible first molars with/without induction of experimental periodontitis (EP) in C, control rats; Pb, lead-treated rats (A); HX, hypoxic rats (B); PbHX, lead-treated hypoxic rats (C). Lines in each graph show animals submitted to EP. Data are reported as means \pm SD (15 rats per group. EP was induced in half of the animals of each group). Equal letters indicate no significant differences. A significant difference between groups was chosen as $p < 0.01$ determined by two-way ANOVA followed by Student–Newman–Keuls Multiple Comparison Test. Down: Photographs of one animal per group selected randomly. Scale bar 1 mm.

epidemiologic investigations in China western territory have showed that the immigrants in the plateau have a higher morbidity with periodontitis. Moreover, chronic exposure to lead significantly affects oral health among exposed workers and strongly correlates with increasing level of blood lead among them. The most common adverse effects of lead on dental health of exposed workers were the significant increase in the prevalence of periodontal diseases, caries, missed and filled teeth and dental abrasions.³ The deleterious effects on periodontal and dental tissues, which we recently reported by means of Pb and HX, aimed us to investigate in the same rat

model, local and systemic inflammatory parameters linked to periodontal disease in rats with or without experimental periodontitis (EP). We used the ligature-induced periodontitis in rats as an experimental model where ligation acts as a mechanical trauma on the gingival area, reducing tissue integrity, allowing host–plaque interaction and bacterial plaque-formation.¹³

To establish the effect of Pb and HX as risk factors for periodontitis, we evaluated the production of plasmatic TNF α because it was demonstrated to be an important mediator in the pathogenesis of this disease allowing the entrance of

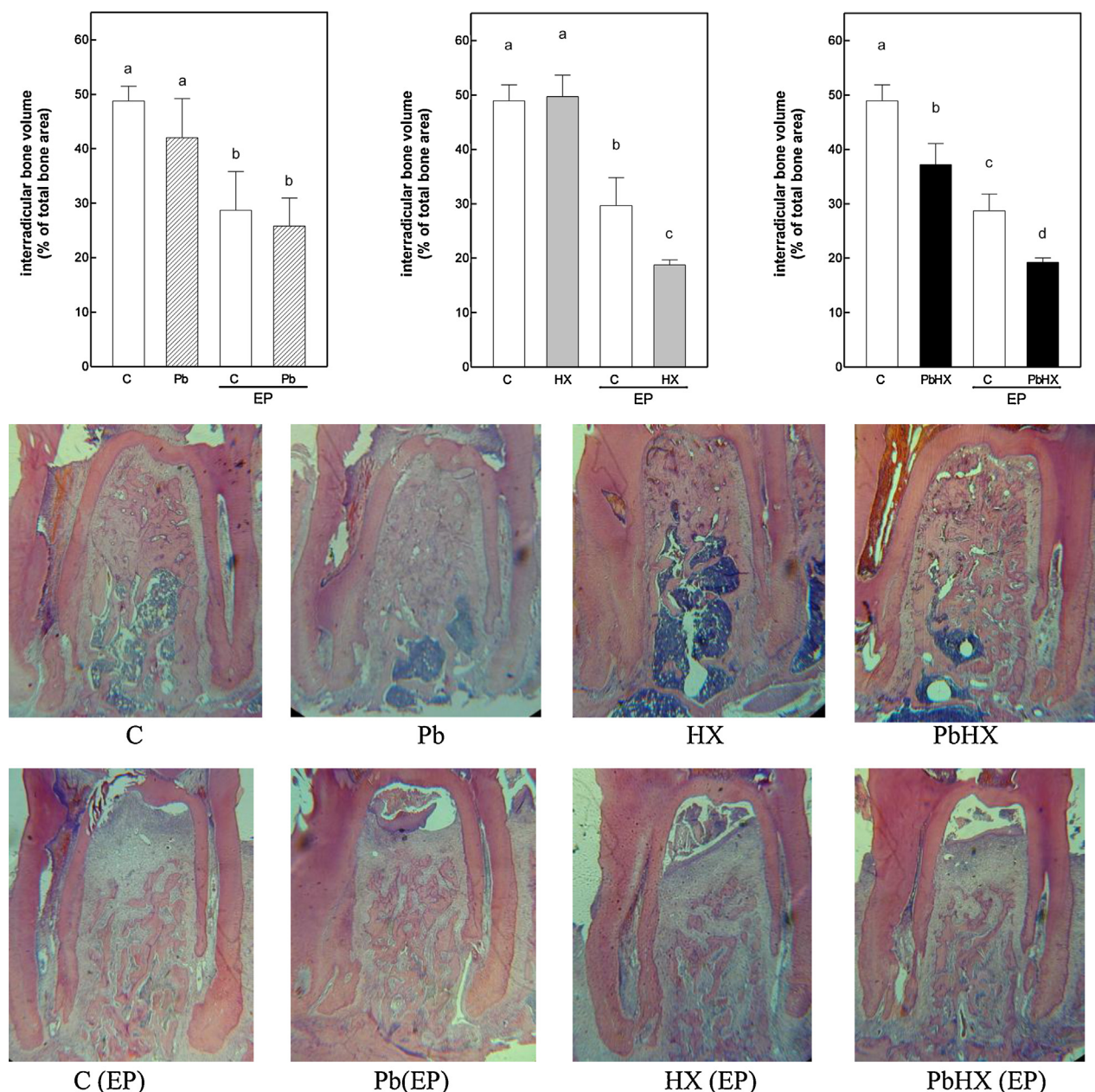


Fig. 5 – Upper: Interradicular bone volume after Pb and HX treatments in rats with 14-days experimental periodontitis (EP) in C, control rats; Pb, lead-treated rats (A), HX, hypoxic rats (B), PbHX, lead-treated hypoxic rats (C). Lines in each graph show animals submitted to EP. Data are reported as means \pm SD (15 rats per group). EP was induced in half of the animals of each group. Equal letters indicate no significant differences. A significant difference between groups was chosen as $p < 0.01$ determined by two-way ANOVA followed by Student–Newman–Keuls Multiple Comparison Test. Down: Photographs of transverse slides of the longitudinal sections of the mandibular interradicular bone of one animal per group selected randomly. Resected hemimandibles stained with H&E were observed under a stereomicroscope ($\times 2.5$).

inflammatory cells into sites of infection, promoting bone resorption and stimulating eicosanoid release, especially prostaglandin E₂.¹⁴ Previously reported studies showed a release of TNF α in another experimental model of periodontitis induced by exposure to lipopolysaccharide (LPS) from gingival tissues.¹⁰ Surprisingly, we found a lack of response in rats exposed to Pb and HX, simultaneously. These findings could be due to a greater activation of the

hypothalamus-pituitary-adrenal axis, with increased levels of corticosterone which leads to lower values of TNF α .

Periodontitis causes oxidative stress, whose consequences occur in the oral cavity and in most distant organs.¹⁵ Patients with periodontitis have a significantly higher level of TBA-RS than healthy people and this suggests that TBA-RS of gingival tissue are closely associated with periodontal status.¹⁶ In this study we found that rats chronically intoxicated with lead

showed significant higher values of TBA-RS content in gums. However, TBA-RS content was significantly higher in SMG only by means of HX. We hypothesise that these differences between gums and SMG values could be due to the local deleterious effect induced by lead intoxication versus the systemic effect of hypoxia, since gums are daily exposed to lead acetate in drinking water while SMG are more distant organs responding to general immunological status. Anyway, other authors concluded that intermittent hypobaric hypoxia not produces significant imbalance in redox status, since not increase oxidative stress assessed by measurements of plasma TBARS and catalase and superoxide dismutase in erythrocytes.¹⁷

The increase of SMG PGE₂ content observed in rats subjected to EP is consistent with inflammatory states as those seen in gingival tissues of patients suffering periodontal disease.¹⁸ High levels of PGE₂ in the SMG were previously reported to be associated to periodontitis, and are in concordance with salivary hipofunction observed in these conditions which also produce additional deleterious effect contributing to the progression of the disease.⁵ Moreover, the highest levels of PGE₂ content observed in the SMG of rats exposed to lead intoxication and hypoxia environment, simultaneously, could explain the spontaneous bone loss observed in these rats, and shows clearly the existence of crosstalk between oral pathologies and the SMG.

Bone loss was determined by the distance method in spite of its limitations because it is recommended for short observation periods (<15 days EP) in relation to the area method.¹⁹ We demonstrated that the hypoxic environment enhanced alveolar bone loss in the buccal sections in animals not submitted to EP. As expected, the molars with EP exhibited significant bone loss which was aggravated by treatments. These results suggest that the damages found in bone tissue due to a periodontal disease could be worsening by the effect of lead intoxication or under hypoxic environment. Moreover, from the analysis of the histological data it seems that combined treatments induce interradicular bone loss even in the absence of periodontitis. We hypothesise that this could be due to the fact that lead intoxication affects osteoblasts, osteoclasts and chondrocytes producing osteoporosis and inhibition of endochondral ossification^{20,21} and that the metal has been found inside hydroxyapatite crystals.²² Lead could also increase the activity of matrix metalloproteinases (MMPs) by direct or indirect mechanisms under means of ROS production.²³ MMPs are a group of enzymes released from inflammatory cells recruited by bacterial infection which play an important role in periodontal disease pathogenesis by cleaving collagen and other matrix proteins. This higher activity induced by Pb would explain the mayor tissue destruction and increased bone loss in the experimental groups.²⁴ On the other hand, the presence of different kind or number of bacteria in the altitude environment compared to a normal one or the greater osteoclastic activity plus the changes in the quantity and quality of saliva might play a role in these alterations.⁴

In conclusion, these results show that lead intoxication under hypoxic environment enhanced not only alveolar bone loss but also some systemic and oral tissues inflammatory parameters, which could aggravate the physiopathological

alterations produced by periodontal disease. Further studies should be necessary to fully understand the underlying mechanisms to evaluate the risk of Pb intoxication in our experimental model.

Funding

This work was supported by research grants from University of Buenos Aires (UBACyT 20020110100014).

Competing interests

Drs. Fernandez-Solari, Bozzini, Mandalunis, Elverdin, Conti & Martinez and dentists Terrizzi and Lee report no conflicts of interest related to this study.

Ethical approval

All animals were treated in accordance with the guidelines and regulations for the use and care of animals of the University of Buenos Aires Ethic Committee and were carried out in accordance with the guidelines of the National Institute of Health (NIH). The use of animal tissues followed an approved animal use protocol.

Acknowledgments

The authors acknowledge the collaboration of physiology laboratory technicians Graciela M. Champin and Elsa Lingua, Department of Physiology, School of Dentistry, University of Buenos Aires.

REFERENCES

- Conti MI, Terrizzi AR, Lee CM, Mandalunis PM, Bozzini C, Piñeiro AE, et al. Effects of lead exposure on growth and bone biology in growing rats exposed to simulated high altitude. *Bulletin of Environmental Contamination and Toxicology* 2012;**88**(6):1033–7.
- Won YS, Kim JH, Kim YS, Bae KH. Association of internal exposure of cadmium and lead with periodontal disease: a study of the Fourth Korean National Health and Nutrition Examination Survey. *Journal of Clinical Periodontology* 2013;**40**(2):118–24.
- El-Said KF, El-Ghamry AM, Mahdy NH, El-Bestawy NA. Chronic occupational exposure to lead and its impact on oral health. *Journal of the Egyptian Public Health Association* 2008;**83**(5–6):451–66.
- Xiao X, Li Y, Zhang G, Gao Y, Kong Y, Liu M, et al. Detection of bacterial diversity in rat's periodontitis model under imitational altitude hypoxia environment. *Archives of Oral Biology* 2012;**57**(1):23–9.
- Amer M, Elverdin JC, Fernández-Solari J, Medina VA, Chiarenza AP, Vacas MI. Reduced methacholine-induced submandibular salivary secretion in rats with experimental periodontitis. *Archives of Oral Biology* 2011;**56**(5):421–7.

6. Leite GAS, Sawan RMM, Teófilo JM, Porto IM, Sousa FB, Gerlach RF. Exposure to lead exacerbates dental fluorosis. *Archives of Oral Biology* 2011;56:695–702.
7. Hamilton JD, O'Flaherty EJ. Effects of lead exposure on skeletal development in rats. *Fundamental and Applied Toxicology* 1994;22(4):594–604.
8. Bozzini CE, Barcelo AC, Conti MI, Martinez MP, Lezon CE, Bozzini C, et al. Unexpected hypoxia-dependent erythropoietin secretion during experimental conditions not affecting tissue O₂ supply/demand ratio. *Kidney International* 1997;51:413–5.
9. Vacas MI, Amer M, Chiarenza AP, Luchelli MA, Mandalunis PM, Elverdin JC. Influence of submandibulectomy on alveolar bone loss in rats. *Journal of Periodontology* 2008;79:1075–80.
10. Ossola CA, Surkin PN, Pugnaroni A, Mohn CE, Elverdin JC, Fernandez-Solari J. Long-term treatment with methanandamide attenuates LPS-induced periodontitis in rats. *Inflammation Research* 2012;61(9):941–8.
11. Maia Mda S, Bicudo SD, Sicherle CC, Rodello L, Gallego IC. Lipid peroxidation and generation of hydrogen peroxide in frozen-thawed ram semen cryopreserved in extenders with antioxidants. *Animal Reproduction Science* 2010;122(1-2):118–23.
12. Mohn CE, Fernandez-Solari J, De Laurentiis A, Bornstein SR, Ehrhart-Bornstein M, Rettori V. Adrenal gland responses to lipopolysaccharide after stress and ethanol administration in male rats. *Stress* 2011;14:216–26.
13. Carvalho RS, de Souza CM, Neves JC, Holanda-Pinto SA, Pinto LM, Brito GA, et al. Effect of venlafaxine on bone loss associated with ligature-induced periodontitis in Wistar rats. *Journal of Negative Results in BioMedicine* 2010;9:13.
14. Stashenko P, Jandinski JJ, Fujiyoshi P, Rynar J, Socransky SS. Tissue levels of bone resorptive cytokines in periodontal disease. *Journal of Periodontology* 1991;62(8):504–9.
15. Ekuni D, Endo Y, Irie K, Azuma T, Tamaki N, Tomofuji T, et al. Imbalance of oxidative/anti-oxidative status induced by periodontitis is involved in apoptosis of rat submandibular glands. *Archives of Oral Biology* 2010;55:170–6.
16. Fowler EB, Breault LG, Cuenin MF. Periodontal disease and its association with systemic disease. *Military Medicine* 2001;166:85–9.
17. Esteva S, Pedret R, Fort N, Torrella JR, Pagès T, Viscor G. Oxidative stress status in rats after intermittent exposure to hypobaric hypoxia. *Wilderness & Environmental Medicine* 2010;21(4):325–31.
18. Preshaw PM, Heasman PA. Prostaglandin E2 concentrations in gingival crevicular fluid: observation in untreated chronic periodontitis. *Journal of Clinical Periodontology* 2002;29:15–20.
19. Dantas AM, Mohn CE, Burdet B, Zorrilla Zubilete M, Mandalunis PM, Elverdin JC, et al. Ethanol consumption enhances periodontal inflammatory markers in rats. *Archives of Oral Biology* 2012;57(9):1211–7.
20. Vahter M, Akkeson A, Liden C, Ceccatelli S, Berglund M. Gender differences in the disposition and toxicity of metals. *Environmental Research* 2007;104:85–95.
21. Carmouche JJ, Puzas JE, Zhang X, Tiyyapatanaputi P, Cory-Slechta DA, Gelein R, et al. Lead exposure inhibits fracture healing and is associated with increased chondrogenesis, delay in cartilage mineralization, and a decrease in osteoprogenitor frequency. *Environmental Health Perspectives* 2005;113:749–55.
22. Hamilton JD, O'Flaherty EJ. Influence of lead on mineralization during bone growth. *Fundamental and Applied Toxicology* 1995;26:265–71.
23. Rizzi E, Castro MM, Fernandes K, Barbosa F, Maisonnave Arisi G, Garcia-Cairasco N, et al. Evidence of early involvement of matrix metalloproteinase-2 in lead-induced hypertension. *Archives of Toxicology* 2009;83:439–49.
24. Kim K, Chung SB, Hawng EY, Noh SH, Song KH, Kim HH, et al. Correlation of expression and activity of matrix metalloproteinase-9 and -2 in human gingival cells of periodontitis patients. *Journal of Periodontal & Implant Science* 2013;43:24–9.